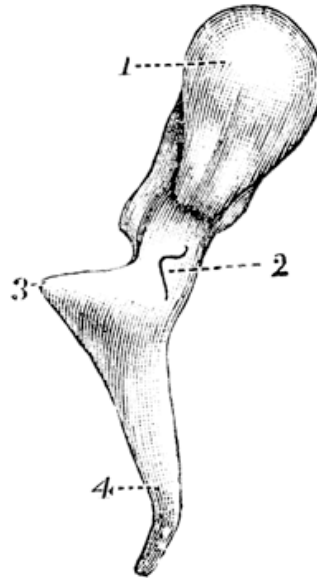


### QUIZ 3 – Anatomy of the middle ear cleft

1. Name the four main parts of the temporal bone.
2. What are the three parts of the middle ear cleft?
3. Name the bone shown and the four labeled parts.



4. What structures lie in the epitympanum?
5. What is the scutum?
6. What diseases can affect the Eustachian tube?
7. Posterior to the mastoid and petrous temporal bone lies a very important structure. What is it? You may have to look at an anatomy textbook to work this out.